

Surgical Indications for Femoroacetabular Impingement With/Without an Acetabular Labral Tear: A Scoping Review

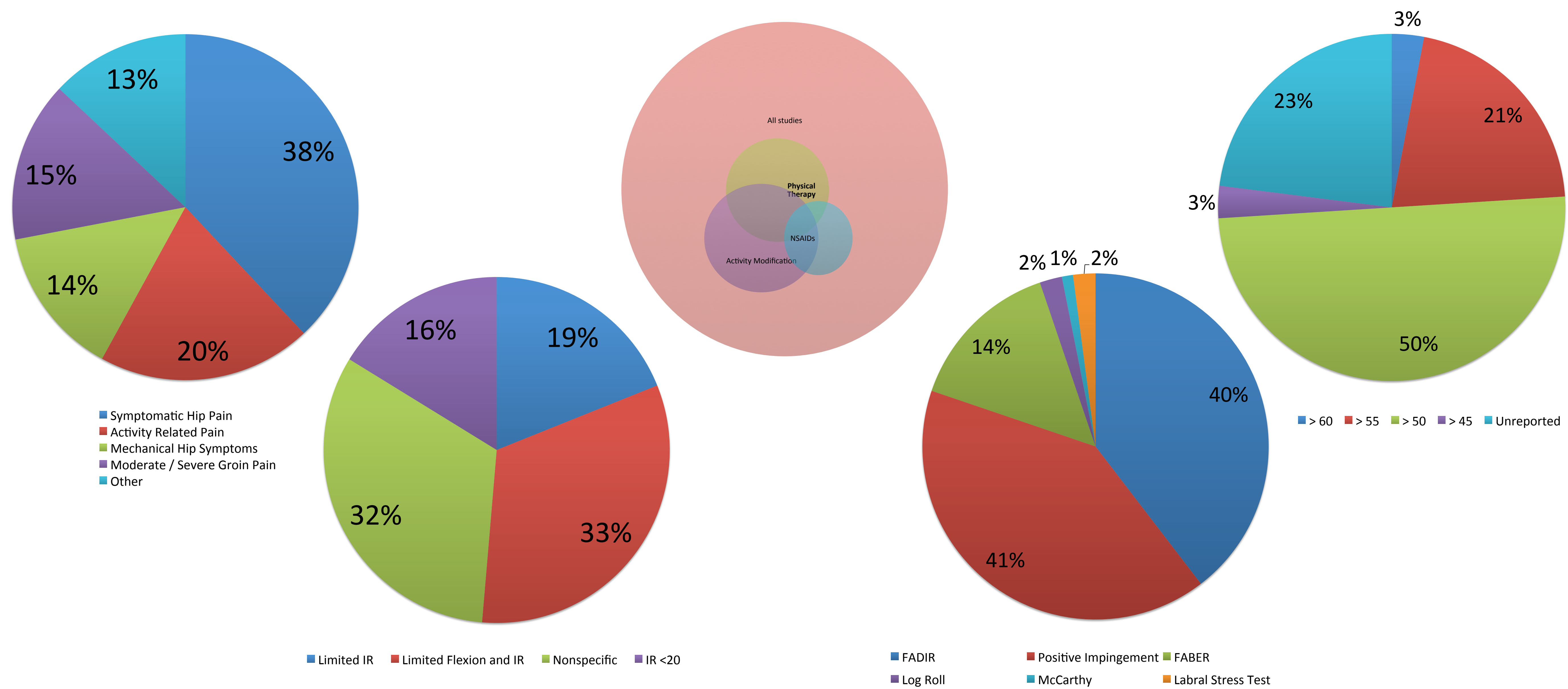
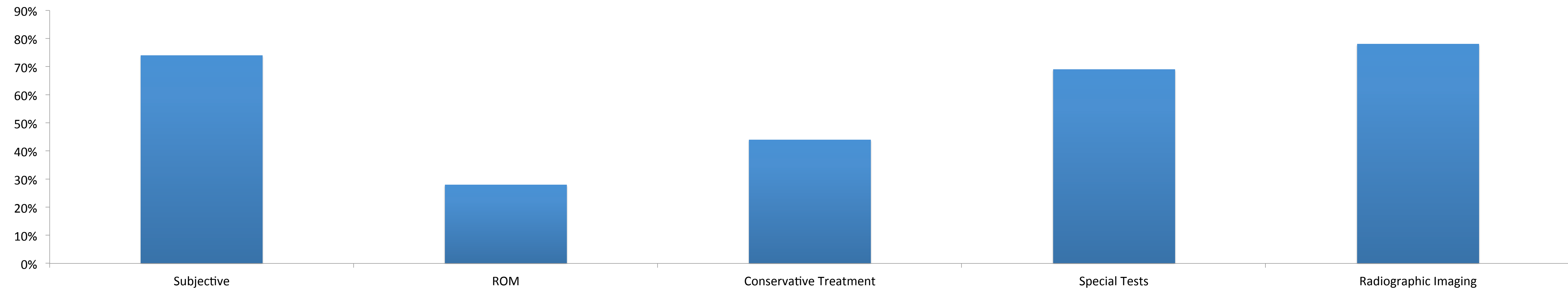
Scott Peters, SPT, Alisha Laing, SPT, Courtney Emerson, SPT, Thomas Joyce, SPT, Kelsey Mutchler, SPT, Michael Reiman, PT, DPT, OCS, SCS, ATC, FAAOMPT, CSCS

Background and Purpose

- The prevalence of FAI is variable across studies reporting of patients presenting with hip or groin pain.
- A comprehensive list of inclusion and exclusion criteria for FAI has recently been proposed. The extent to which this diagnostic criteria is used in current practice is unclear.
- Therefore, the purpose of this review was to analyze and report the indications used for open and arthroscopic surgical treatment of FAI.
- We hypothesized that radiographic evidence of FAI would be the primary indications for surgery; however we expected to find vast differences among surgeons for the other criteria used to identify FAI.

Results

Radiographic imaging (alpha angle, central edge, crossover sign) was a surgical indication in 78% of the included studies. Subjective history was a reported surgical indication in 74% of the studies, and special tests were reported in 69% of studies. Failed non-surgical physical therapy treatment was only reported in 18% of studies as a surgical indication.



	# of Articles	Frequency
Hip pain > 3 months	28	25%
No clinical evidence of inflammatory arthritis changes	70	64%
Hip IR < 20 in 90 hip flexion	6	5%
Lateral center-edge angle > 20	19	17%
Alpha angle > 60, CE angle > 40, or presence of acetabular retroversion	73	66%
Alpha > 60	2	2%
CE Angle > 40	8	7%
Acetabular Retroversion (stating crossover sign)	63	57%
Diagnostic Injection or MRI indicating presence of intra-articular pathology or labral damage	68	62%

Subjects and Methods

- Subjects: 10,078 patients (56.2% male) and 10,698 hips were included in this study. Mean age was 33 years.
- A librarian assisted computer search of Medline, CINAHL, and Embase for articles related to surgical indications for FAI, as well as, the *Preferred Reporting Items for Systematic Reviews and Meta-Analyses* (PRISMA) guidelines were used for the search and reporting phases of this study.
- Inclusion criteria for this review included: studies of subjects with surgical treatment of FAI, studies with the primary purpose of surgery or surgical outcomes for treatment of FAI, and studies with defined indications for FAI surgery.

Clinical Relevance and Conclusions

- Similar to many musculoskeletal conditions, the diagnosis of FAI and need for surgical intervention should be based on a multitude of factors painting a clear clinical picture for the surgeon and treatment team.
- Radiographic findings of FAI have been found in 10-74% of asymptomatic individuals which further supports that the need for FAI surgery should not be based solely on this parameter.
- The rate of surgical intervention for FAI is continuing to escalate despite poorly described and inconsistently reported surgical indications
- The primary surgical indication for FAI surgery is currently radiographic imaging, despite a lack of consensus on the specific modalities and cut-off values necessary for this intervention. It remains unclear which indications determine best surgical outcomes for FAI.